

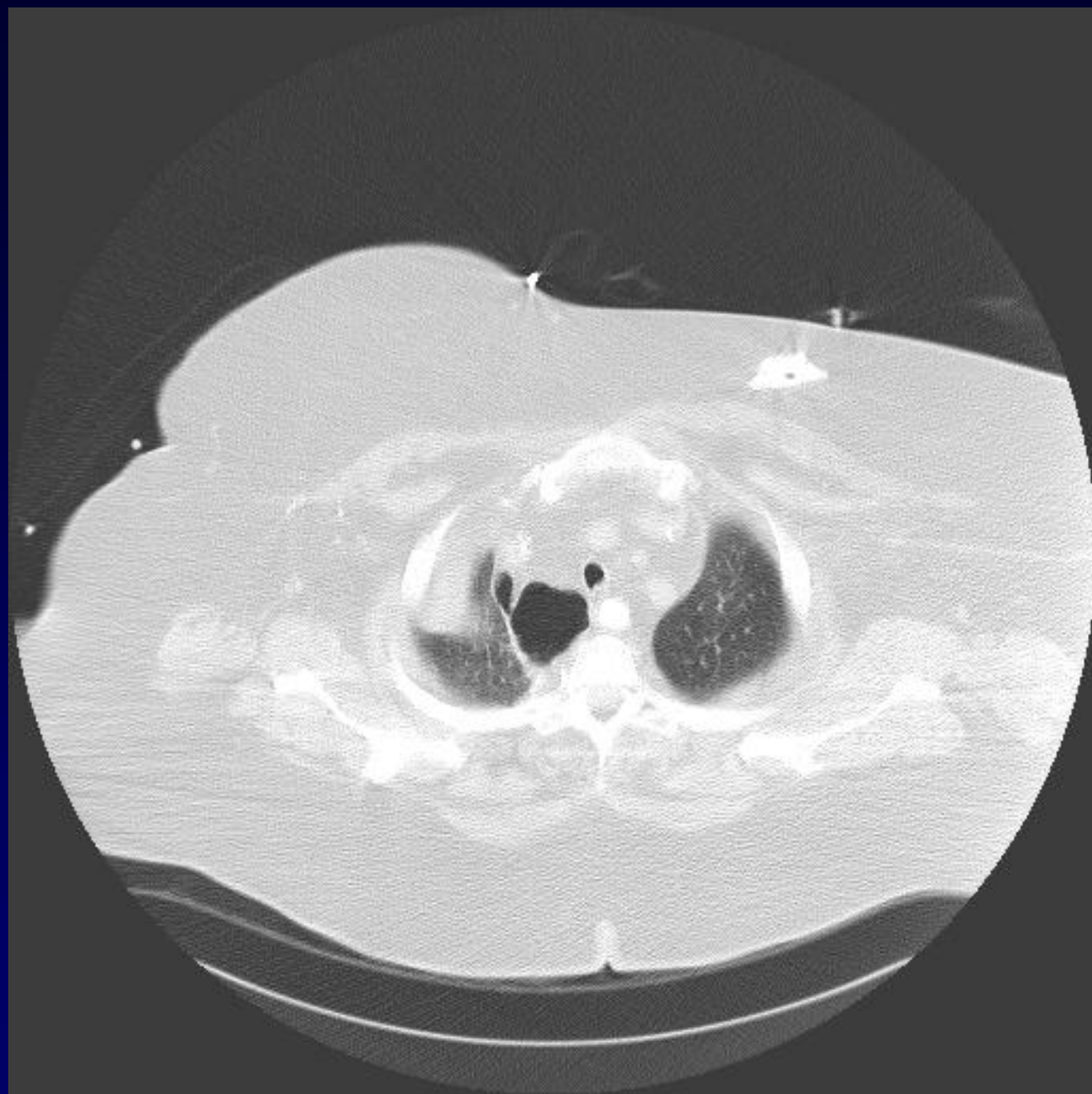


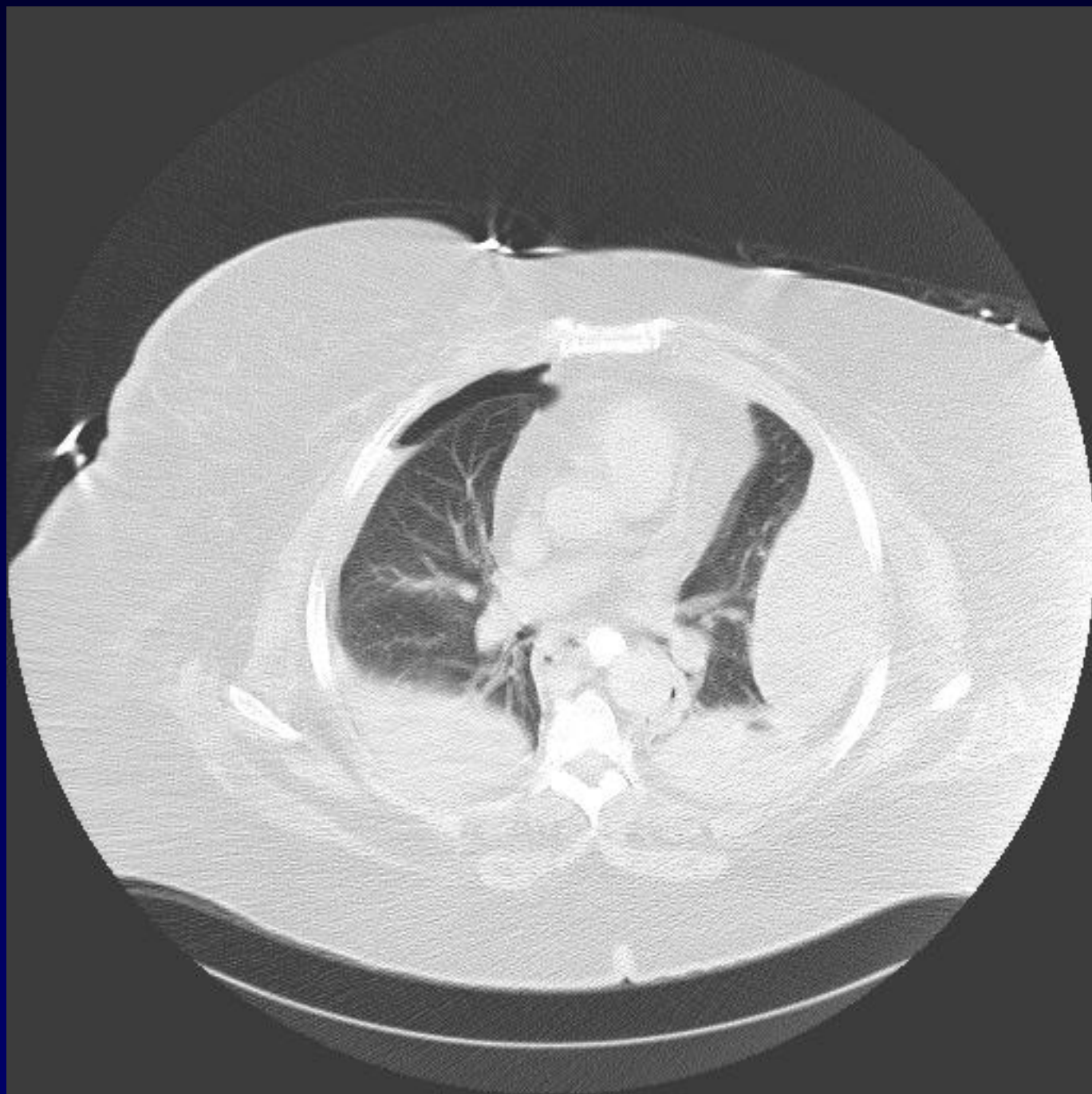
L.METGE

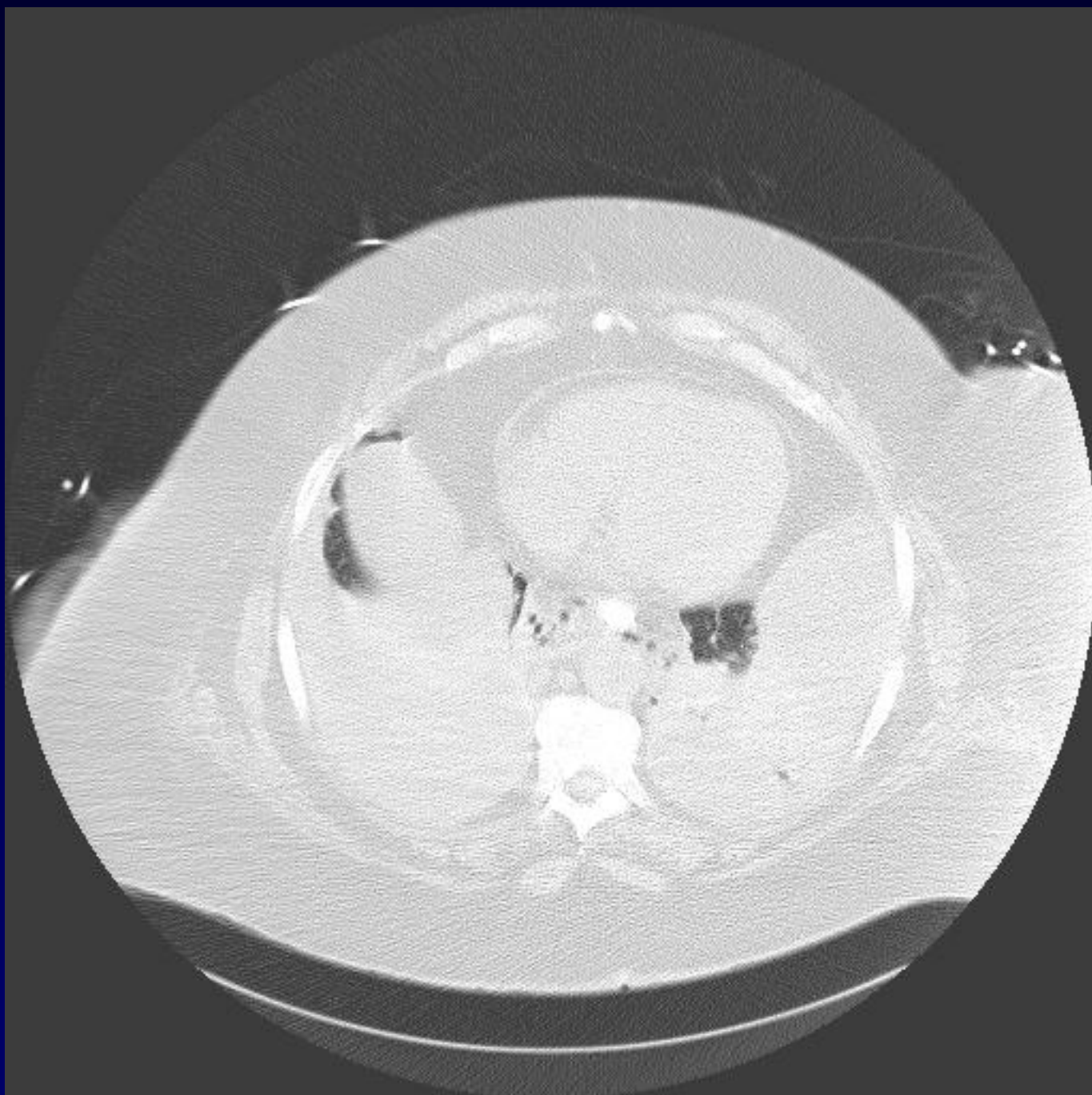
Femme de 57 ans

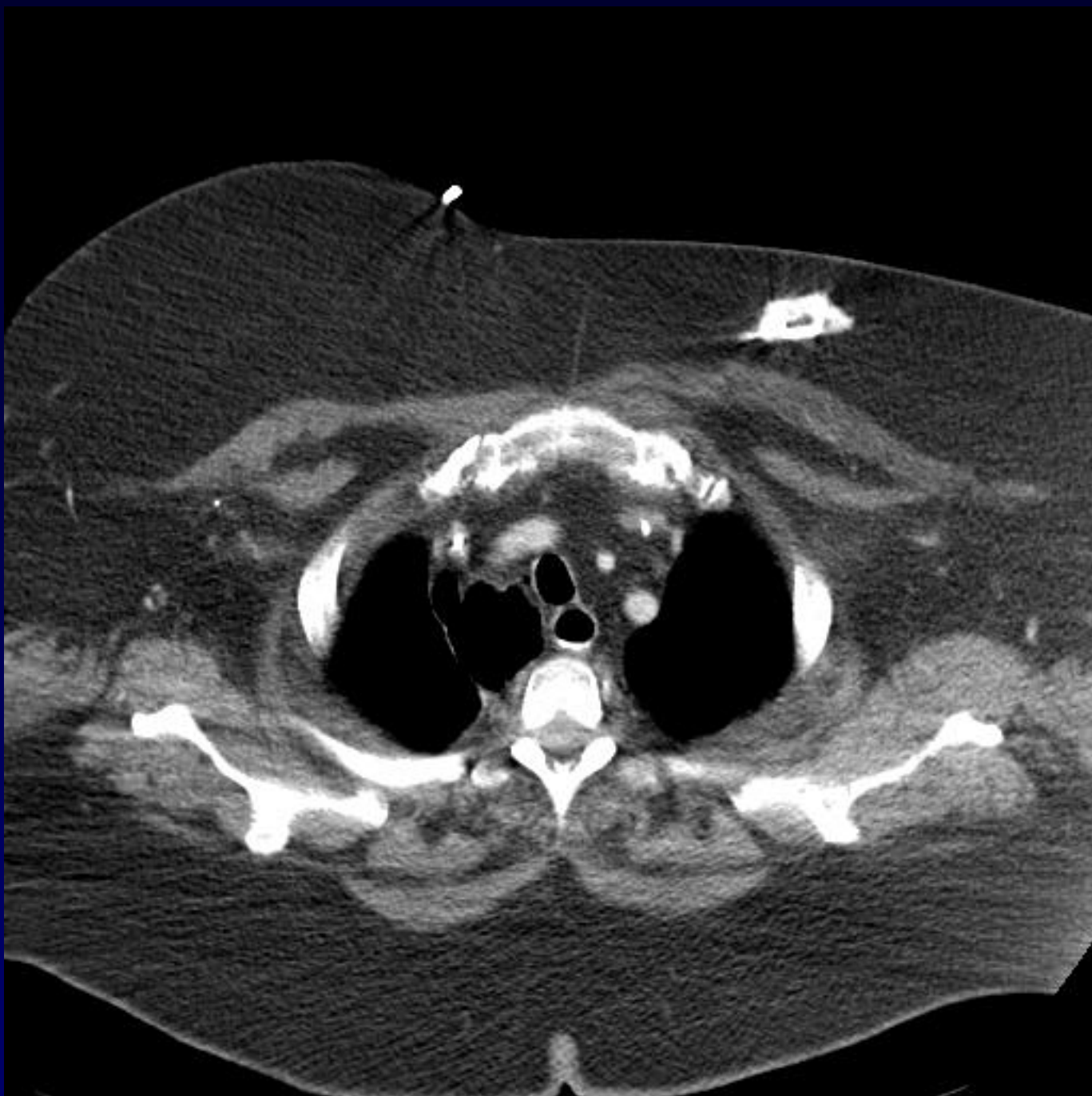Chirurgie bariatrique

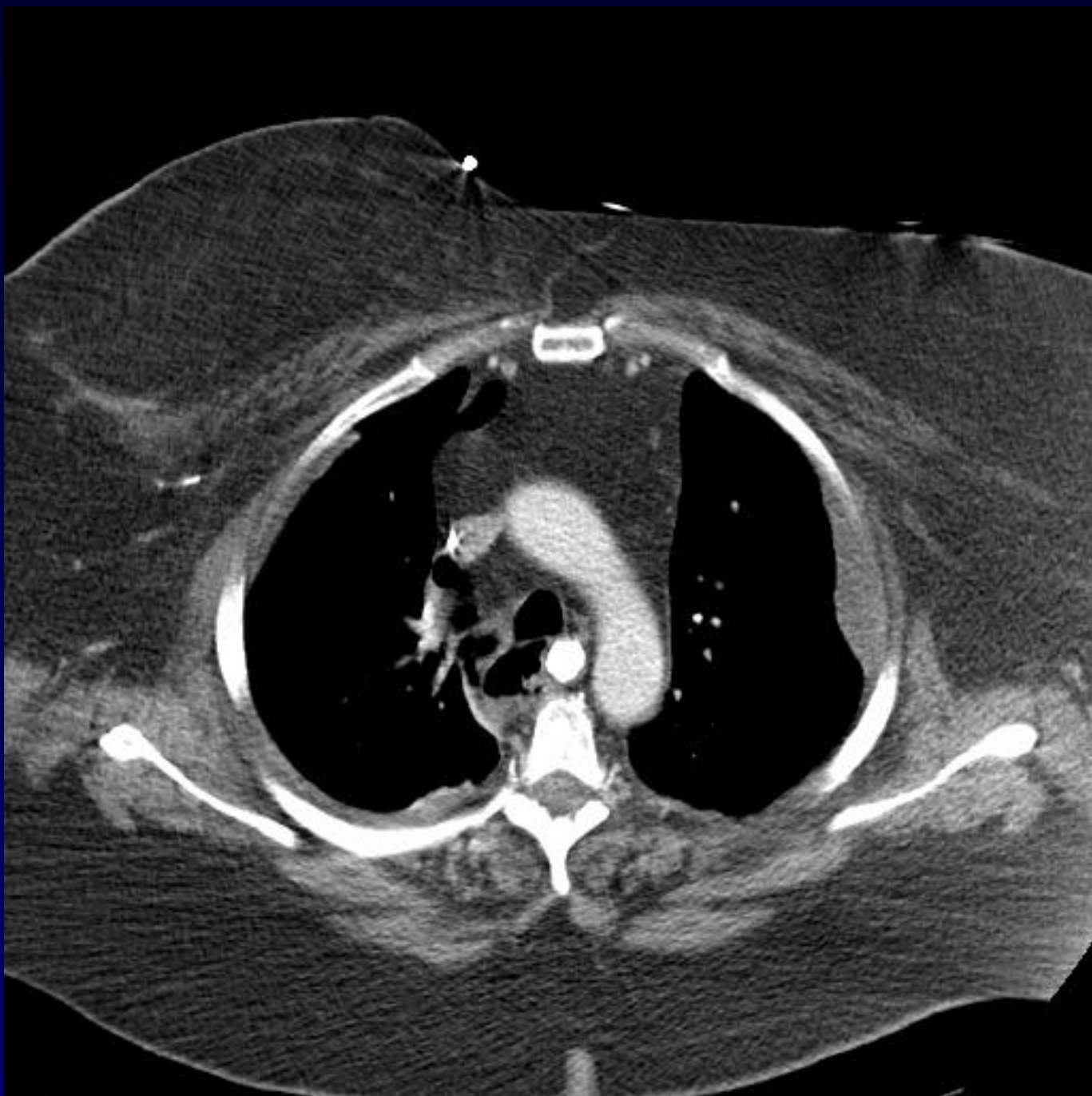
Fièvre

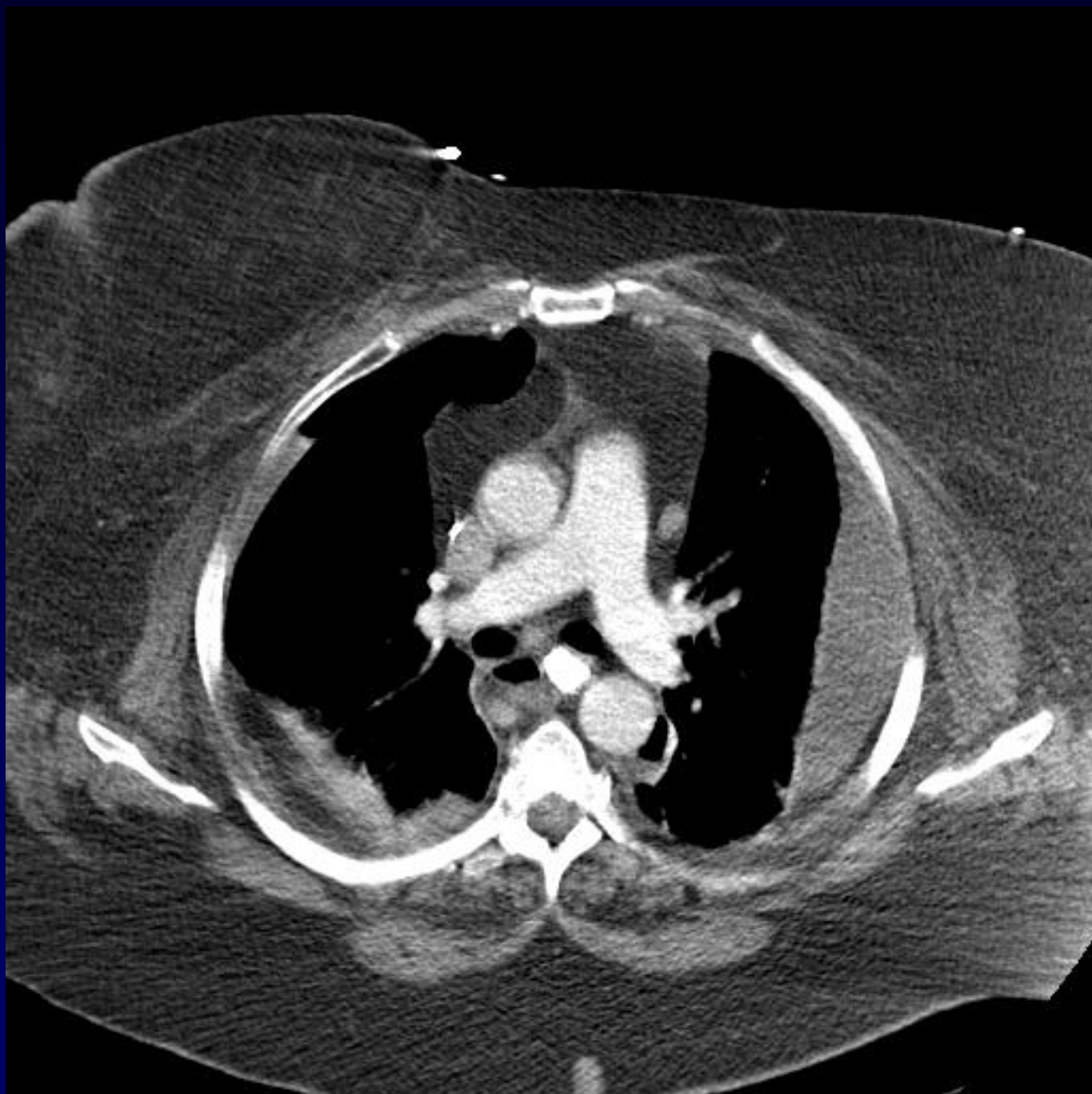


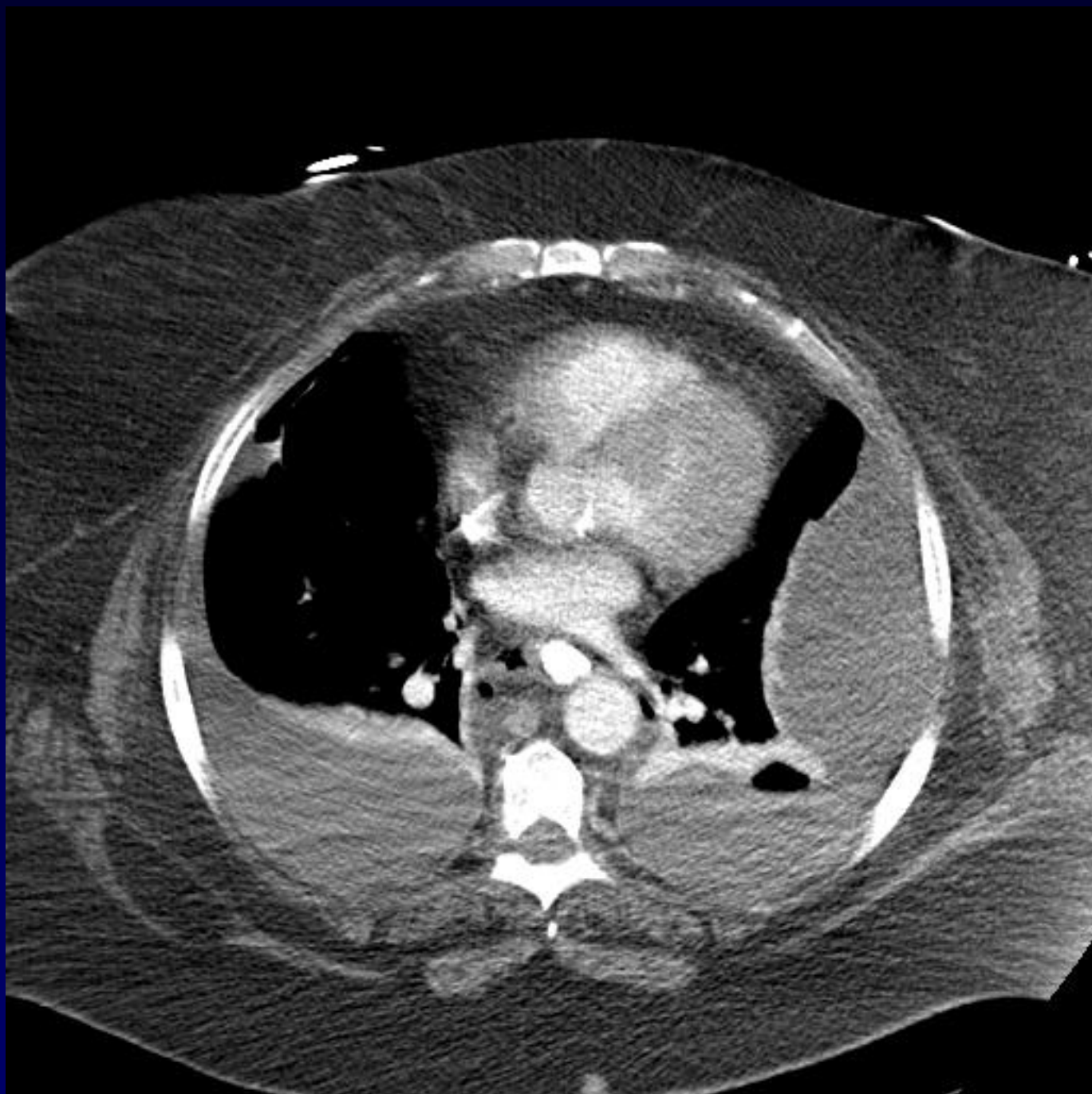


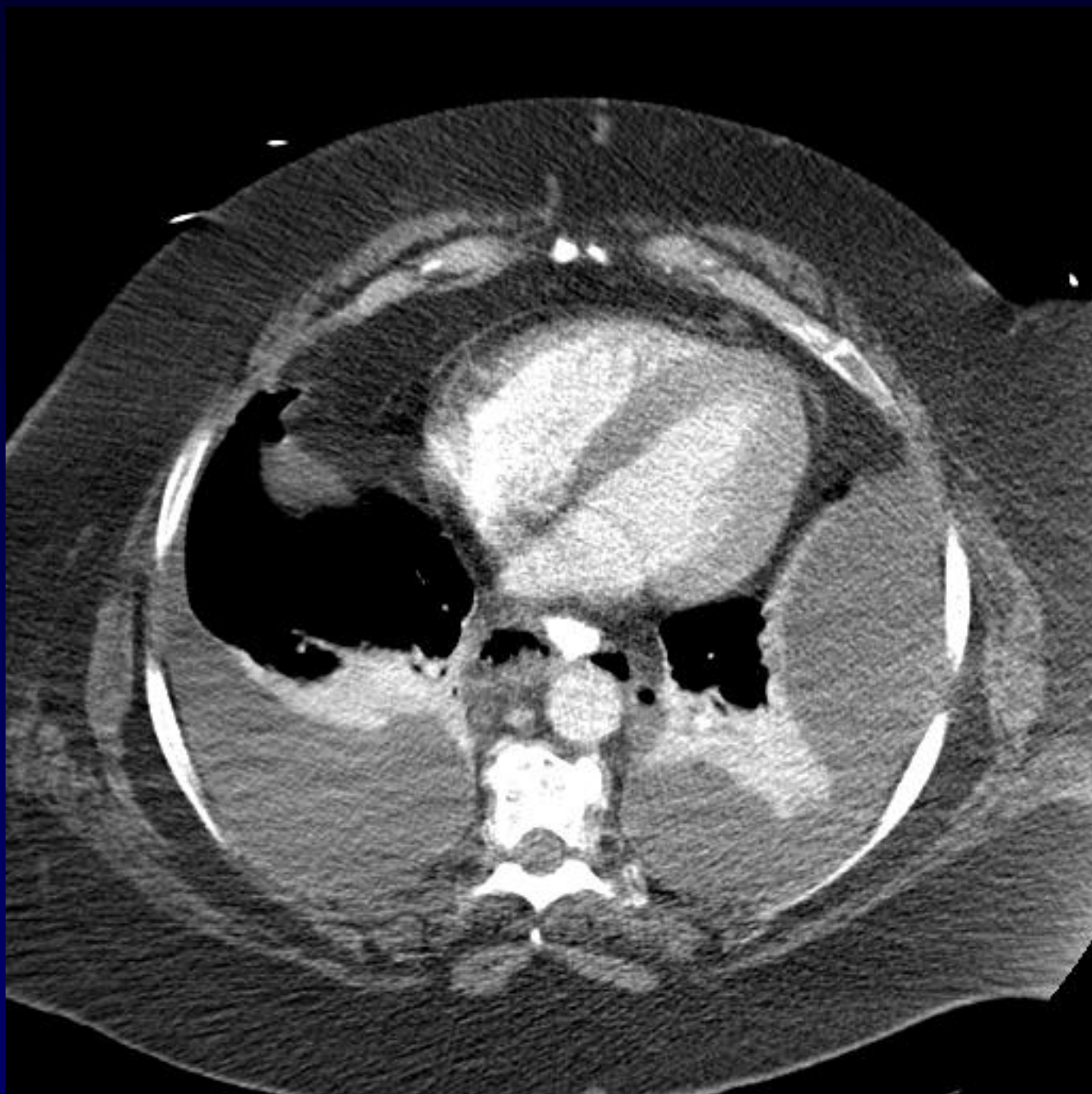


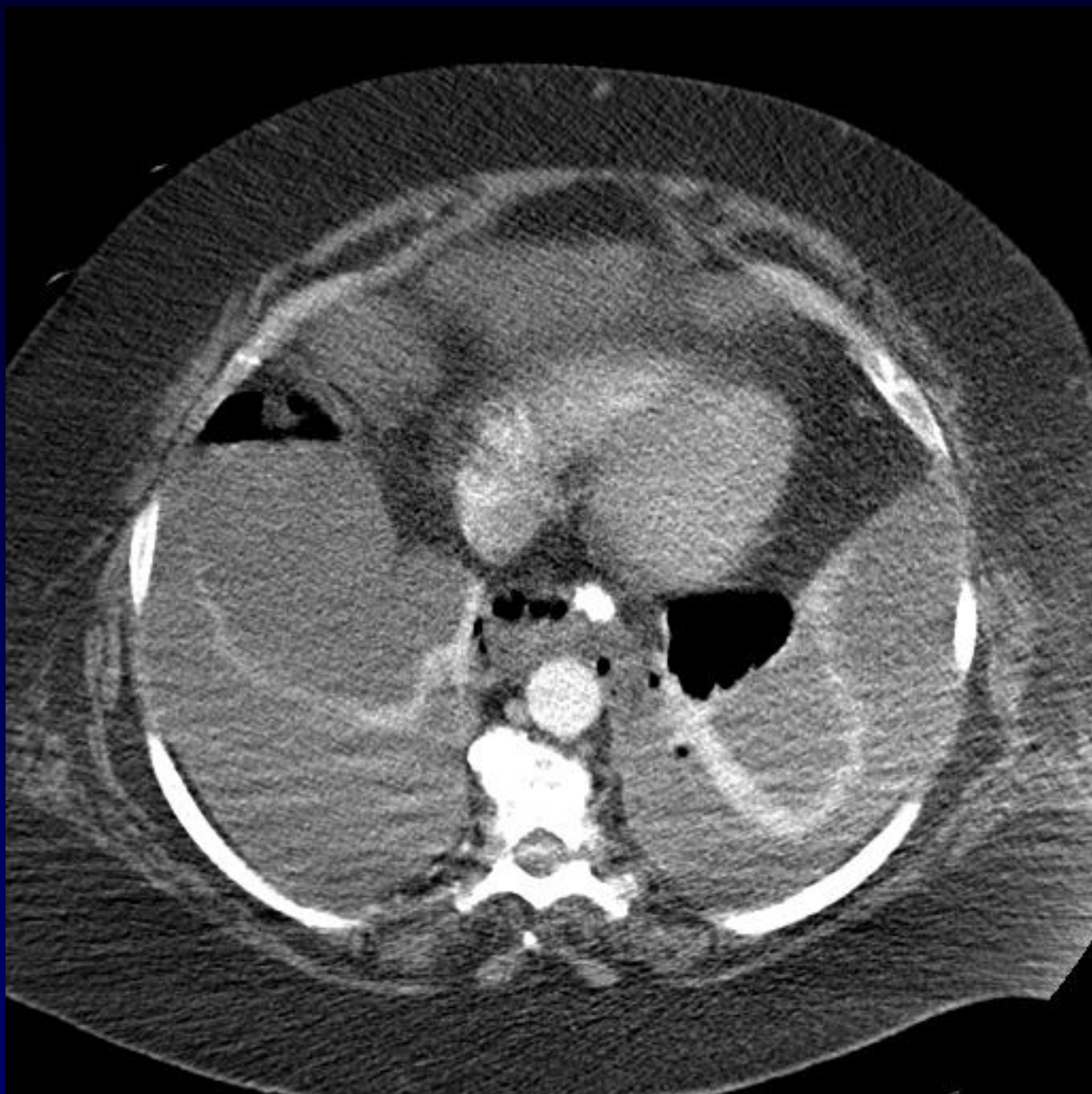












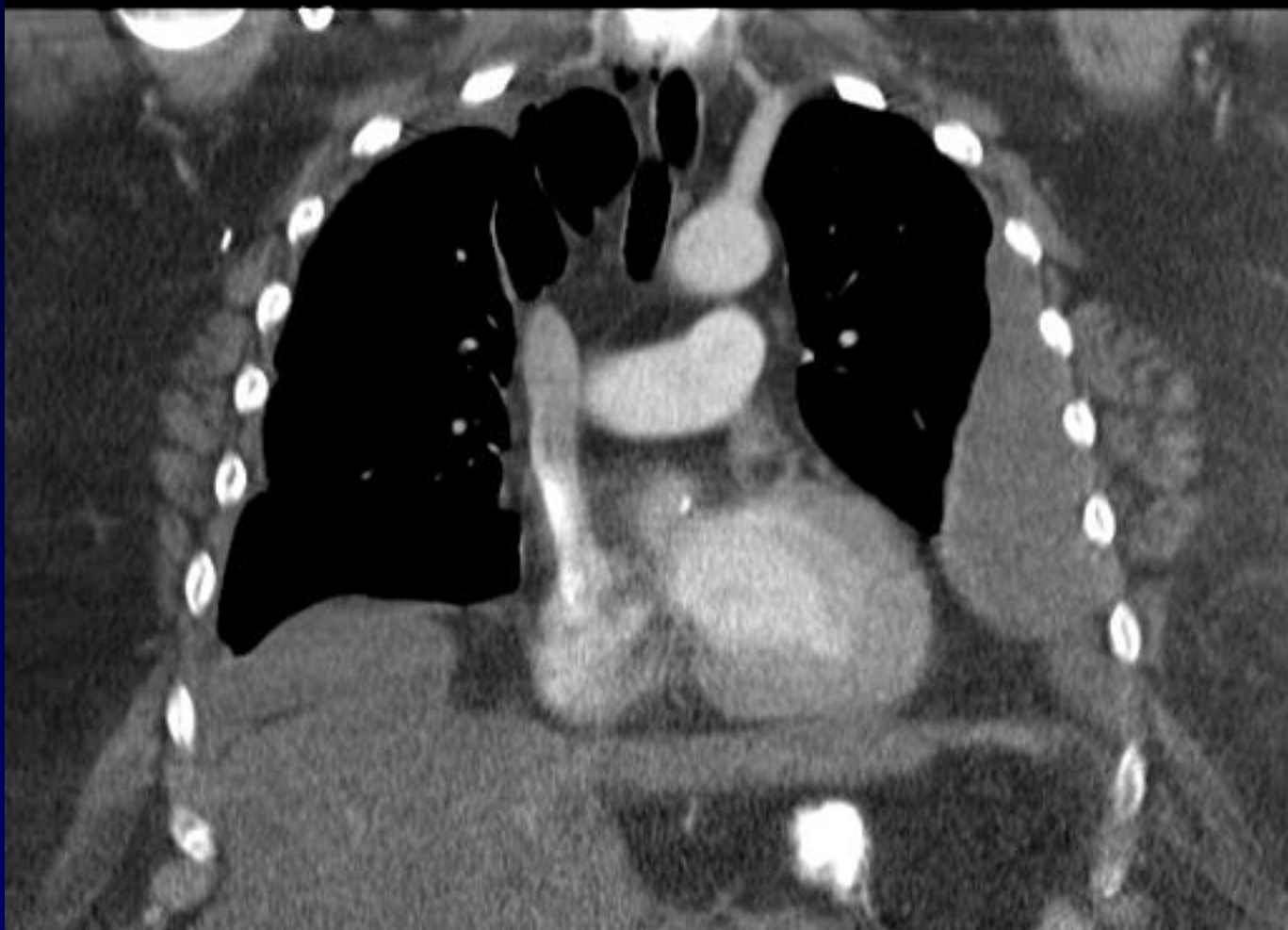

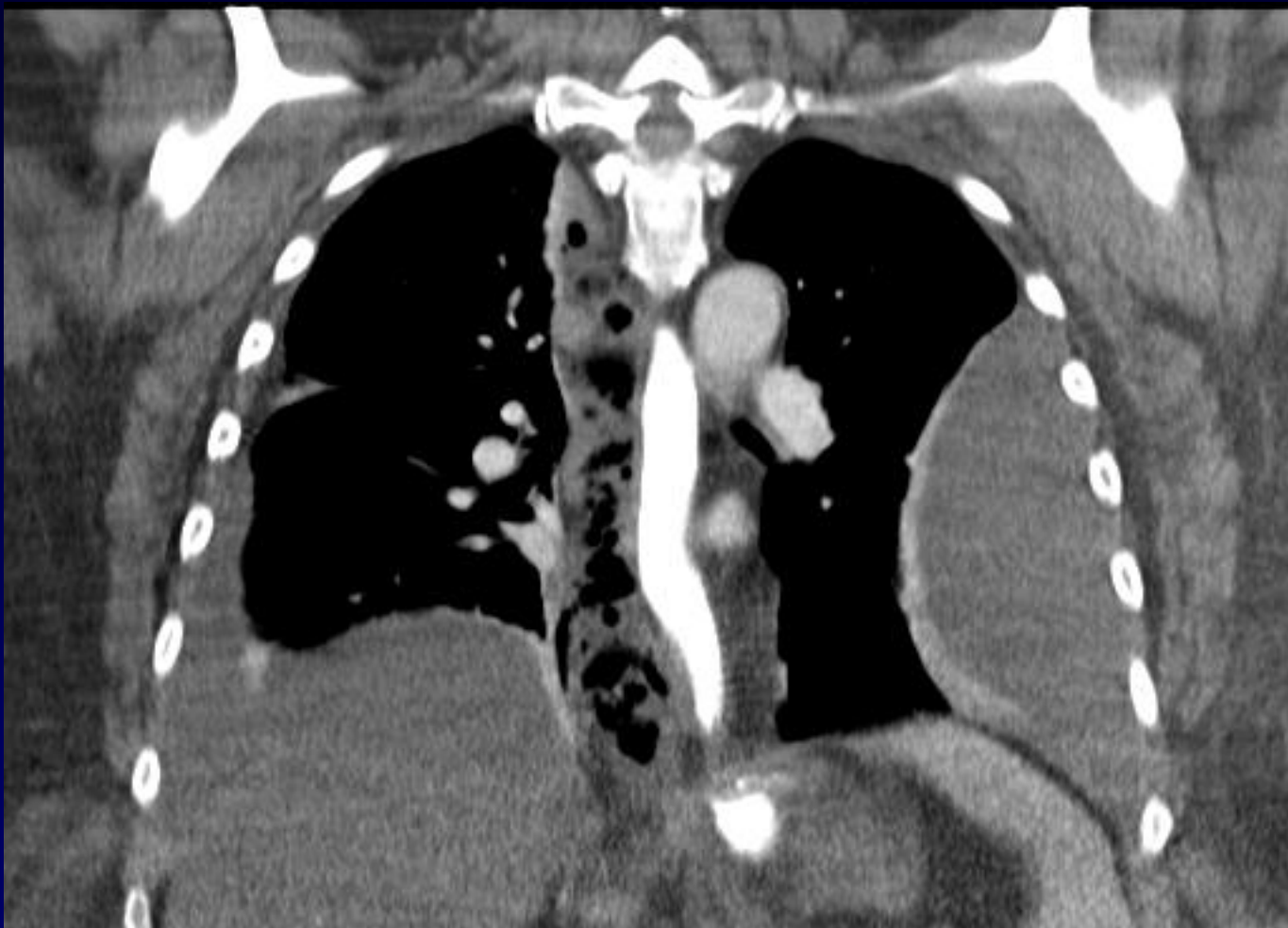Diagnostic ?

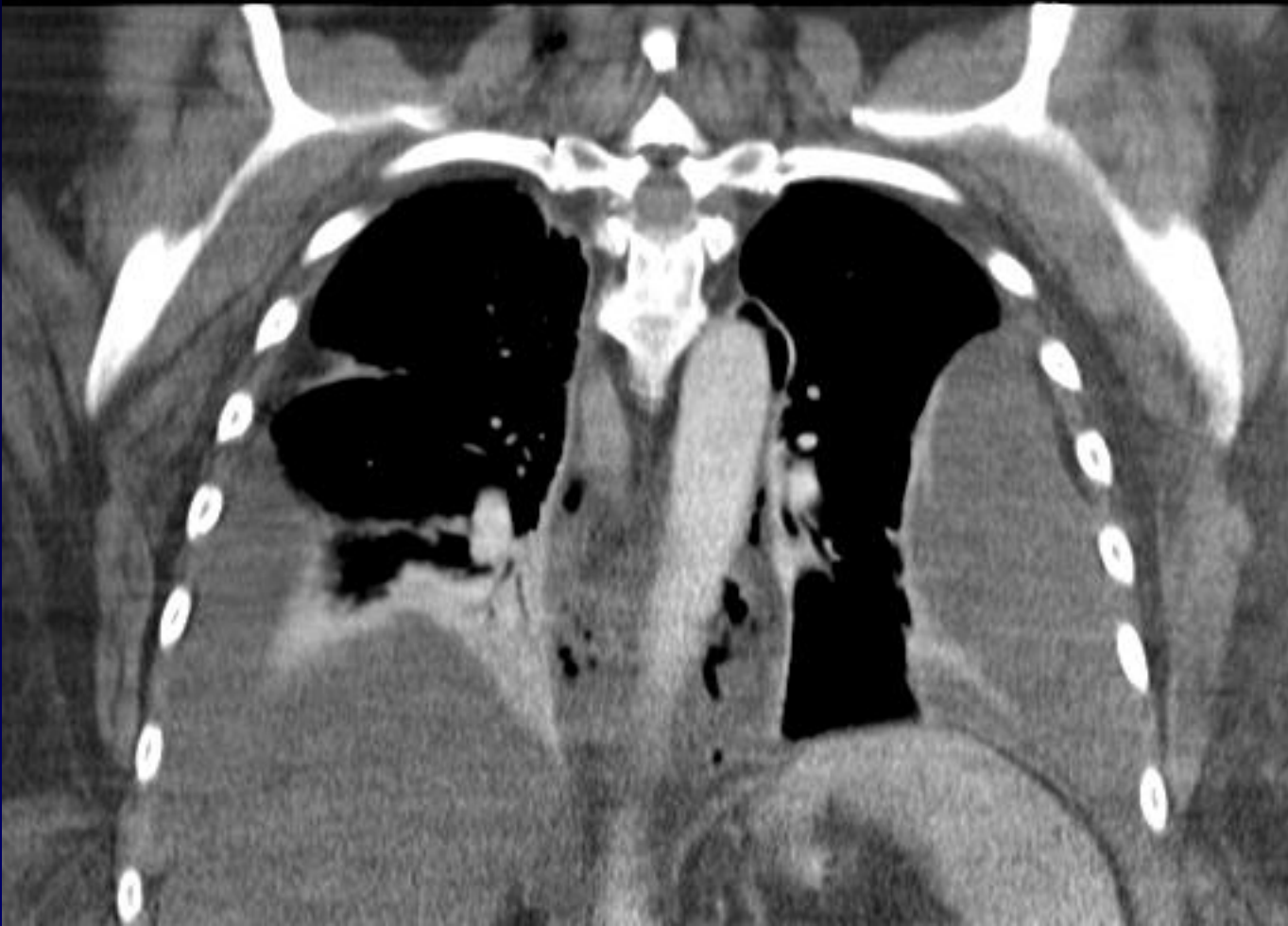

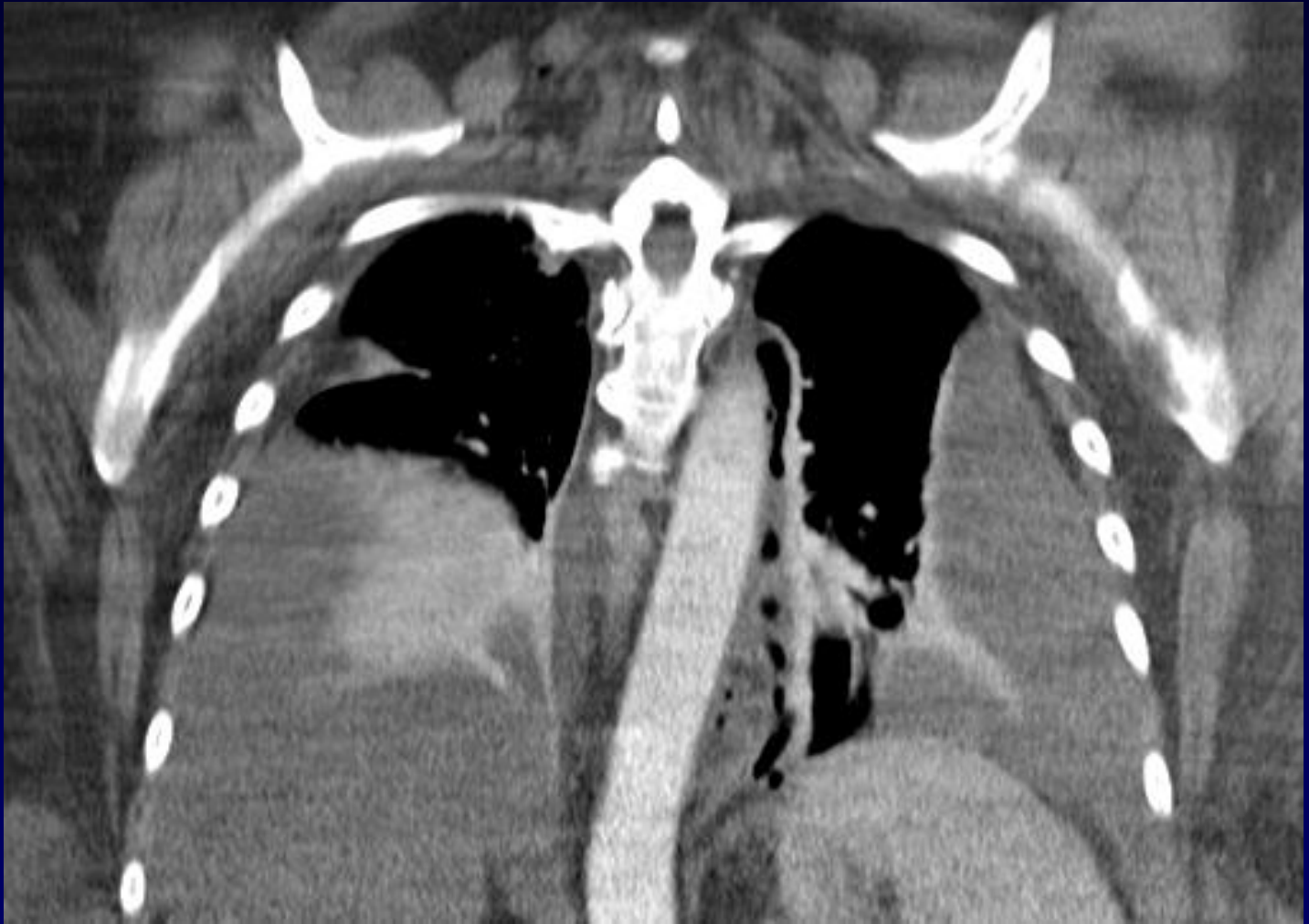Diagnostic

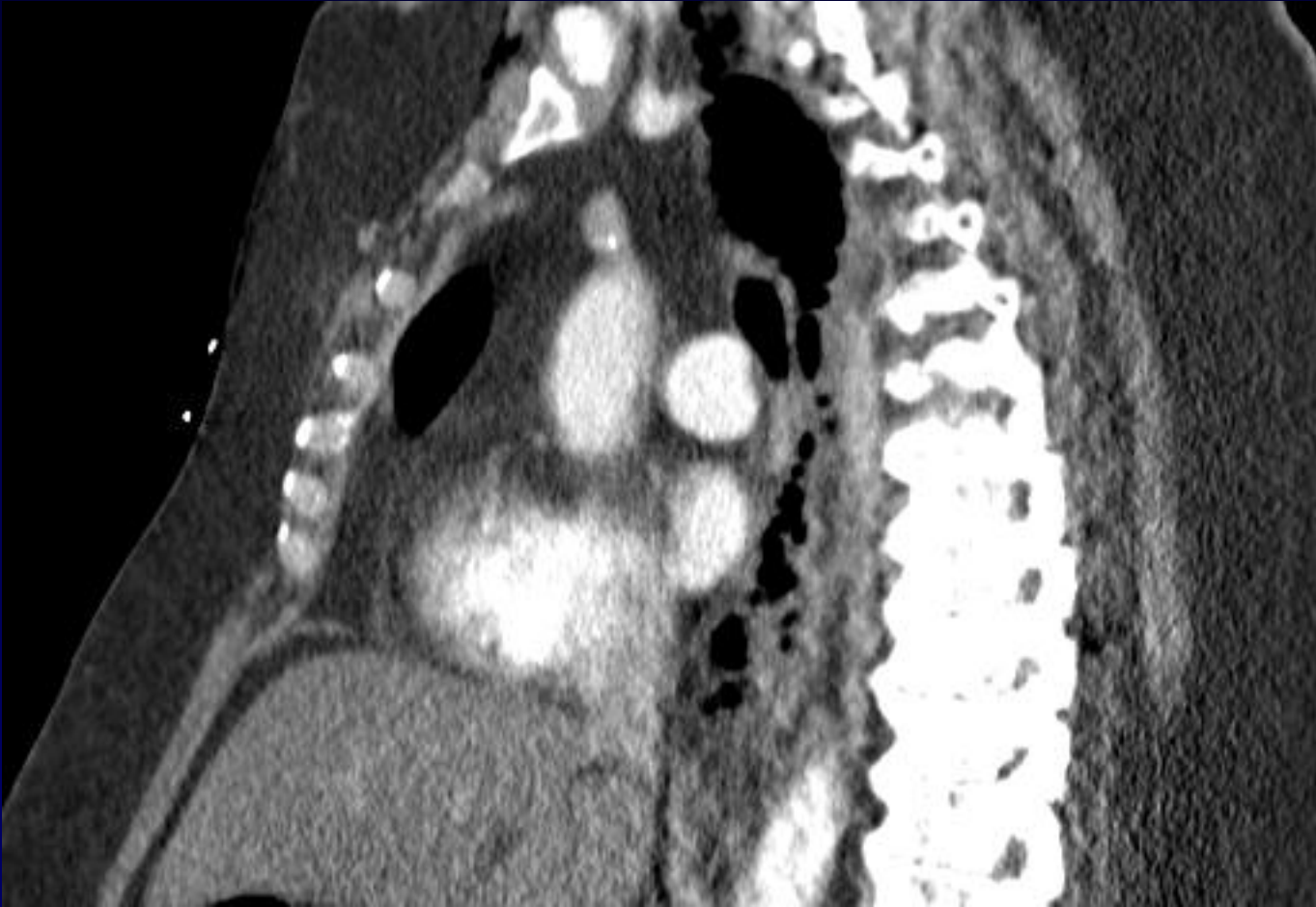
Médiastinite post opératoire
Lâchage de suture abdominale













Complication grave de chirurgie bariatrique

Peu fréquente

Mortalité élevée